



Topic Review

Posterior Chamber Phakic Intraocular Lens: Indications, Contraindications, Technique, and Postoperative Management

Raymond Stein, MD, FRCSC,^{1,2} , Rebecca Stein, MD, FRCSC,³ 

¹ Toronto, Bochner Eye Institute, ² Professor of Ophthalmology and Vision Sciences, University of Toronto, ³ Toronto, Ontario, Bochner Eye Institute

Keywords: Posterior chamber phakic intraocular lens, implantable collamer lens, refractive surgery, implantable contact lens

<https://doi.org/10.57204/001c.75436>

CRO (Clinical & Refractive Optometry) Journal

Posterior chamber phakic intraocular lenses are a crucial option in refractive surgery for both non-presbyopic and presbyopic patients looking to improve vision without removal of the crystalline lens and who may not be candidates for other refractive surgery modalities, such as LASIK and PRK. This article examines the indications, considerations, contraindications, and post-operative complications associated with implantable collamer lens (ICL) surgery. Moreover, it discusses new ICLs available in the market, such as the EVO ICL, as well as the examination factors that should be taken into consideration when electing for refractive surgery.

INTRODUCTION

A posterior chamber phakic intraocular lens is an important consideration in refractive surgery. This type of lens is inserted into the eye that has an intact natural crystalline lens to enhance uncorrected vision. The implantable collamer lens (ICL) is currently the only approved posterior chamber phakic lens in North America. Most eye surgeons and practices refer to this lens as the implantable contact lens. It is a soft, thin lens that can be surgically implanted to correct nearsightedness, farsightedness, and astigmatism, as shown in [Figure 1](#).¹⁻³ This lens offers a long-term alternative to traditional contact lenses.

A posterior chamber phakic lens is inserted into the space between the iris and the crystalline lens and is a reversible option for refractive surgery ([Figure 2](#)). Other options include LASIK, PRK, Intrastromal Lenticule Extraction, and Refractive Lens Exchange, but unlike these procedures, the phakic lens does not require tissue removal. It is rare for patients to have a phakic implant extracted except at the time of cataract surgery. A comparison of the benefits and risks of the most common refractive procedures is provided in [Table 1](#).

Patients who are candidates for a phakic implant should receive counseling on the ICL procedure and be provided with a comparison of ICLs, laser vision correction, and RLE to make an informed decision ([Table 2](#)). Clinicians should have a comprehensive understanding of the procedure's indications, contraindications, surgical technique, and post-

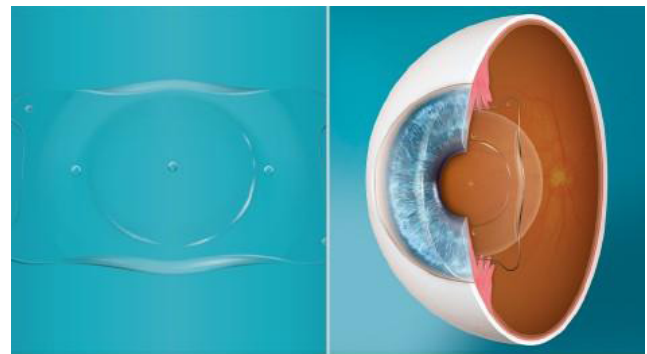


Figure 1. Phakic posterior chamber lens (EVO ICL) with a central opening in the optic that is inserted behind the iris and in front of the crystalline lens.

operative complications to provide adequate pre- and post-operative care.

THE EVO IMPLANTABLE COLLAMER LENS

Globally, over two million ICLs have been implanted, and it has been approved for clinical use in Canada for over 20 years.⁴ The innovative EVO ICL design with a central microscopic opening of 0.36 mm in the optic is available for myopic eyes since approval in Canada in 2016. This design enhances fluid dynamics around the crystalline lens, improves aqueous circulation, and reduces the risk of pupil-

a Author Correspondence

Contact Dr. Raymond Stein MD, FRCSC,
Bochner Eye Institute
40 Prince Arthur Ave,
Toronto, ONtario
416 960 2020

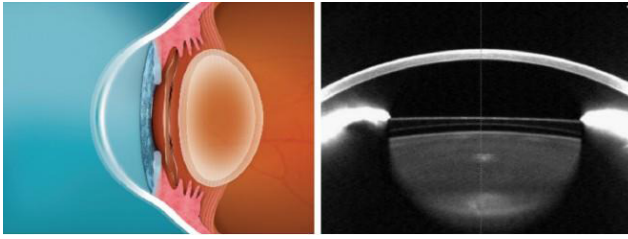


Figure 2. Cross-sectional view that shows the position of the phakic posterior chamber lens in the ciliary sulcus with vaulting over the crystalline lens.

lary block glaucoma.¹ The fluid flow has resulted in improved hydration of the crystalline lens and a resultant low incidence of cataract formation with long-term data from Europe.⁵ Additionally, the central port eliminates the need for peripheral laser iridotomies, which makes the entire surgical process easier for patients.

Unlike typical intraocular lenses that are stored on the shelves in eye operating rooms, the ICL is custom ordered and manufactured according to the refractive error and ideal length of the lens. The lens’s length determines the vault over the crystalline lens, with the aim of achieving satisfactory clearance while avoiding excessive vault that could lead to a shallow anterior chamber.

Based on a review of 67 preclinical studies and clinical reports, which evaluated 1,905 eyes with an average follow-up period of 12.5 months for effectiveness and 4,196 eyes with a weighted average follow-up period of 14.0 months for safety, the EVO ICL has been deemed both safe and effective in treating a wide range of refractive errors.¹ The EVO ICL has demonstrated its effectiveness through high levels of postoperative uncorrected visual acuity, refractive predictability, and stability. Moreover, the safety data indicate lower rates of anterior subcapsular cataract and pupillary block as compared to earlier models.¹ These improvements in safety and efficacy make the EVO ICL a desirable choice for both patients and surgeons.

Patients have reported significant improvements in quality of vision and quality of life using the Quality of Life Impact Refractive Correction questionnaire.⁶ In a peer-reviewed comparison of optical quality and intraocular light

scattering, the EVO lens with a central port did not significantly affect the lens’s optical performance compared to older ICLs without the central port.⁷

Unlike corneal refractive surgical procedures, the ICL implantation does not alter the cornea’s shape, so the selection of IOL power for future cataract surgery is not affected. Keeping the cornea intact also eliminates the potential for a dry eye.¹

In a study of 351 eyes, the postoperative uncorrected visual acuity of the EVO ICL group was 20/20 or better in 97%, 100%, 100%, 100%, 100%, and 85% of eyes at 1, 3, and 6 months and 1, 3, and 5 years after the surgery, respectively.⁸ This indicates that the postoperative uncorrected visual acuity was excellent and stable for up to 5 years after the surgery.⁸ Furthermore, the reports also suggest high accuracy and refractive predictability.

EVO ICLs are made of Collamer, a biocompatible material containing collagen bonded with a UV-absorbing chromophore into a poly-HEMA based copolymer, offering UV protection and minimizing inflammation.⁹

WHAT ARE THE INDICATIONS FOR ICL SURGERY?

ICLs are typically recommended for patients who have moderate to severe refractive errors that cannot be effectively corrected by other methods such as laser vision correction or are deemed at high risk of retinal complications with a RLE. The following are the anatomic, refractive, and patient specific indications for the use of ICLs:

ANATOMIC

1. Myopic ICL: Anterior chamber depth > or = 2.8 mm
2. Hyperopic ICL: Anterior chamber depth > or = 3.0 mm

REFRACTIVE ERROR

1. Myopia -3 to -18 D
2. Hyperopia +3 to +10 D
3. Astigmatism +1.00 to +6.0 D

	Implantable Contact Lens	Laser Vision Correction	Refractive Lens Exchange
Refractive Error Correction	Yes	Yes	Yes
Presbyopia Correction	Monovision	Monovision	Multifocal or Monovision
Tissue Removal	No	Yes	Yes
Reversible	Yes	No	No
Induced Higher-Order Aberrations	No	Yes	Yes
Ectasia Risk	No	Yes	No
Intraocular Complications Risk	Yes	No	Yes
Retinal Detachment Risk	Low	Low	Higher

Table 1. Comparison of Implantable Contact Lens, Laser Vision Correction, and Refractive Lens Exchange.

Non-Presbyope		Presbyope	
<p>Laser Vision Correction Candidate (all required)</p> <ul style="list-style-type: none"> Refractive Error in normal range Satisfactory Corneal Thickness No Significant Ocular Surface Disease No evidence of Keratoconus, Pellucid Marginal Degeneration, or Ectasia 	<p>Not a Candidate for Laser Vision Correction (one or more)</p> <ul style="list-style-type: none"> Refractive Error Too High Corneas Too Thin Stable Keratoconus, Pellucid Marginal Degeneration, or Ectasia with Satisfactory Best-Corrected Spectacle Acuity Radial Keratotomy and High Hyperopia Patient Preference for Reversible Procedure 	<p>Examination Factors (one or more)</p> <ul style="list-style-type: none"> High Myopia with axial length >25 mm History of Previous Retinal Detachment History of Lattice Degeneration Patient under 60 years of age Patient Preference for Reversible Procedure 	<p>Examination Factors (one or more)</p> <ul style="list-style-type: none"> All Refractive Errors with axial length <u>=</u> or < 25 mm Early Lens Changes Patient desires multifocal implant over monovision and acceptance of increased risk of Retinal Detachment
<p>Laser Vision Candidate</p> <ul style="list-style-type: none"> LASIK PRK Intrastromal Lenticule Extraction 	<p>ICL Candidate if</p> <ul style="list-style-type: none"> Myopia: AC Depth > or = 2.8 mm Hyperopia: AC Depth > or = 3.0 mm <p>ICL Candidate</p> <ul style="list-style-type: none"> Distance OU (PrePresbyopic or Presbyopic) Monovision (Presbyopic) 	<p>RLE</p> <ul style="list-style-type: none"> Extended Depth of Focus IOLs (Mini-Monovision) Multifocal IOLs Standard Monovision 	

Table 2. Refractive Surgery Decision Tree

It is important to understand that if there is a residual refractive error, then laser vision correction can be performed to optimize uncorrected vision.

PATIENT CONSIDERATIONS

- High myopia:** ICLs are a good option for patients with moderate to high myopia, who cannot be treated with laser vision correction.¹⁰⁻¹² Unlike with laser vision correction, the ICL does not cause flattening of the cornea and therefore reduces the risk of induced spherical aberration, a higher-order aberration that can potentially make driving at night more difficult. For highly myopic presbyopic patients, the ICL is a safer option than RLE because of a reduced risk of retinal detachment and maintaining levels of accommodation by not removing the crystalline lens. Monovision is an option to aid in reading.
- High hyperopia:** Although a high percentage of hyperopes will not qualify for the ICL because of an anterior chamber depth of < 3.0 mm, this is a good option in the pre-presbyopic patient.^{13,14} Presbyopic patients usually prefer improvement in distance and near and are often satisfactory candidates for RLE. Since the hyperopes usually have shorter axial lengths compared to high myopes, there is a lower risk of retinal tears and retinal detachment.
- Keratoconus:** Patients with stable keratoconus and a satisfactory best-corrected acuity of 20/30 or better, may benefit from ICL surgery.¹⁵⁻¹⁷ For patients less than 35 years of age, corneal crosslinking is usually recommended to stabilize the corneas, and then to wait approximately 12 months for refractive stability prior to ICL surgery. Older patients with topographic

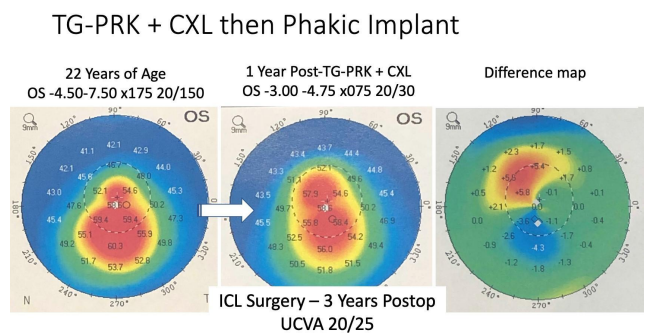


Figure 3. A 22 year old, with advanced keratoconus and a best-corrected spectacle acuity of 20/150, underwent TG-PRK and CXL and achieved a best corrected acuity of 20/30. One year after achieving refractive and topographic stability, an ICL procedure was performed, which resulted in an uncorrected acuity of 20/25.

and refractive stability do not require corneal crosslinking prior to ICL surgery. In patients with reduced best-corrected acuity, a topographic-PRK (TG-PRK) ablation and crosslinking may be indicated (Figure 3). TG-PRK is an excimer laser ablation of the cornea that is guided by topography to reduce irregular astigmatism by flattening steep areas and steepening flat areas. If best-corrected acuity is satisfactory, then an ICL could be performed.

- Radial keratotomy:** Patients may be overcorrected because of excess flattening from the radial incisions.¹⁸ Although they can have success with a RLE, the IOL calculations are less accurate following radial keratotomy, and in addition there is a greater risk of

retinal tears and retinal detachment because of the longer axial length in the myopic eye.

5. **Piggyback lens:** Patients that have had cataract surgery or refractive lens exchange can be treated with an ICL inserted in the ciliary sulcus in front of the initial implant.¹⁹ This can result in a quick improvement in uncorrected acuity.
6. **Thin corneas:** Some patients may have corneas that are too thin to undergo laser vision correction. ICL can be a good alternative in these cases. Patients that have had laser vision correction and have regressed with thin corneas may be satisfactory candidates for an ICL as an enhancement. In this situation patients may have any degree of refractive error.
7. **Dry eye syndrome:** Traditional contact lenses can be uncomfortable for people with dry eye syndrome. In this situation, laser vision correction may be contraindicated as the surface curvature changes may aggravate a dry eye.
8. **Desire for improved visual acuity:** Implantable contact lenses can provide sharper and clearer vision than traditional contact lenses or glasses, which can be appealing for people who value their visual acuity. When the vision is corrected closer to the nodal point of the eye, vision is typically better than with optical aids.

WHAT ARE THE CONTRAINDICATIONS FOR THE ICL?

While ICLs can be a safe and effective option for many patients with refractive errors, there are certain contraindications that may make some individuals unsuitable candidates for the procedure.²⁰ These may include:

1. **Age:** Implantable contact lenses are generally not recommended for individuals under the age of 21, as their refractive error may still be changing.
2. **Pregnancy or breastfeeding:** Hormonal changes during pregnancy and breastfeeding can affect the refractive error, which can make it difficult to determine the proper ICL prescription.
3. **Unstable refraction:** Individuals whose vision prescription has changed significantly within the past year may not be good candidates for ICL surgery.
4. **Primary Open Angle or Narrow Angle Glaucoma.**
5. Patients with **Fuchs' Dystrophy** or a low endothelial cell count.
6. Visually significant **Cataracts.**
7. Patients who have significant **Amblyopic** or **Blind** in the fellow eye.
8. **Anterior chamber depth** (as measured from the corneal endothelium to the anterior lens capsule) of < 2.8 mm for myopic eyes, and < 3.0 mm for hyperopic eyes.

SURGICAL PROCEDURE

The ICL procedure is performed under topical anesthesia without the need for injections or sutures. Patients are usually given a mild sedative to make them more relaxed. In the operating room, if a toric implant is to be inserted the axis for the implant is marked on the cornea with the patient sitting up. The patient is then positioned in a supine position on the operating room bed, and the periorbital area and eye is cleaned with a disinfectant solution like Betadine. A surgical drape is applied to keep the operating field sterile. A 1 mm incision and 3 mm incision are made in the peripheral cornea in the limbus area. The smaller incision is used for injection of an intracameral anesthetic, a viscoelastic to maintain space in the anterior chamber and protect the crystalline lens, and for a thin instrument to position the haptics behind the iris and position the ICL in the correct orientation. The larger incision is used to insert the ICL through an injector system. Through the injector, the folded lens opens slowly in the anterior chamber and then the haptics are tucked behind the iris so the lens is positioned in the posterior chamber in front of the crystalline lens. The wounds are hydrated to decrease leakage, and no sutures are required. An antibiotic is injected to decrease the risk of infection. Patients are given an antibiotic, steroid, and nonsteroidal drops to be used postop for a few weeks.

POSTOPERATIVE CARE

Patient follow-up is typically at one day, one to two weeks, and then one month. The examination includes measuring uncorrected acuity, best-corrected acuity, intraocular pressure, and slitlamp examination. The pupils should be equal in size, there should be a satisfactory vault of the ICL over the crystalline lens, and the anterior chamber should not be shallow.

WHAT ARE THE POTENTIAL POSTOPERATIVE COMPLICATIONS?

The surgeon and the surgical team are primarily responsible for discussion of the benefits, and risks including potential complications of a posterior chamber phakic implant. The phakic lens is generally considered safe and effective for correcting vision problems and have a low risk of complications. However, as with any surgical procedure, there is a small risk of complications.

Regular follow-up appointments with an eye doctor can help to monitor for any potential complications and ensure the best possible outcome.

1. **Elevated intraocular pressure:** In the first 24 hours, there is a risk of elevated intraocular pressure because of the viscoelastic trapped behind the ICL.²¹ Patients may complain of headache, nausea, or vomiting. The use of a pressure lowering drop, an oral agent like Diamox, can be helpful. Prior to the development of the EVO ICL for myopia, and currently

- with the hyperopic ICL that doesn't have a central opening, pupillary block glaucoma could occur.²² In this situation, a YAG iridotomy needs to be repeated, and this is usually successful in lowering the eye pressure. In rare situations, the ICL can be too large resulting in a significant vault and shallow anterior chamber.²³ In this situation, the pressure is very difficult to control, and the ICL may need to be removed. If the elevated pressure is seen only after a week and the anterior chamber has a satisfactory depth, then this is usually a reaction to the steroid drops. Discontinuing the steroid usually results in the pressure returning to normal within a week.
2. **ICL touching the crystalline lens:** This is related to a sizing issue with the ICL with the lens being too short. This is extremely rare and may require removal of the lens with replacement of a larger ICL.
 3. **Infection:** As with any intraocular surgical procedure, infection is a very rare complication and associated with a decrease in vision, redness of the eye, and a significant anterior chamber reaction often with a hypopyon.²⁴ Infections in the eye can be serious and can lead to vision loss if not treated promptly.
 4. **Vitreous floaters:** A vitreous detachment often results in the onset of floaters. These can be bothersome but, in most patients, decrease over time.
 5. **Retinal tear/Retinal Detachment:** A vitreous detachment can lead to a retinal tear and the potential of a retinal detachment.²⁵ A study conducted a retrospective chart review to evaluate the risk of retinal detachment (RD) following implantable collamer lens (ICL) implantation in myopic eyes. The study, which spanned a period of 10 years, concluded that ICL implantation did not increase the risk of RD compared to myopic eyes that were not operated on.²⁶ Previous research has suggested that the incidence of pseudophakic RD is higher in eyes with certain risk factors such as longer axial length (>25 mm), a history of lattice degeneration or ocular trauma, a previous history of RD in the other eye, younger age (< 60 years), male gender, and intraoperative complications like posterior capsular rupture. In myopic eyes (>25 mm), there is a six-fold increased risk of pseudophakic RD, and this risk is further amplified by another six-fold in younger myopic patients (<60 years).²⁷ To provide context, individuals younger than 60 years who are myopic and undergo lens-based surgery have a 12-fold increased risk of pseudophakic RD.²⁷
 6. **Glare or halos:** If the ICL optic is not well centered around the pupil then patients can have symptoms that may not improve.²⁸ In this situation, repositioning the lens can be helpful. In the case of the EVO ICL there may be light scatter from the central opening.²⁹ Patients may experience some glare and halos, but this typically decreases secondary to a brain mechanism called neuroadaptation. The brain sees some unwanted images and simply suppresses these over time resolving the symptoms.
 7. **Residual refractive error:** The accuracy of the refractive correction is very accurate with the ICL as there is essentially no significant healing that takes place compared to laser vision correction with epithelial remodeling of the cornea. In addition, regression is rare compared to laser vision in high prescriptions. If a residual refractive error does occur, rather than exchanging the ICL, the safest option is laser vision correction to refine the vision.
 8. **Corneal endothelial cell loss:** During ICL surgery, there is a risk of loss to the cells that line the back of the cornea.^{30,31} Based on the clinical data collected through 5-7 years postoperative, the calculated rate of loss of endothelial cell density (ECD) was 1.8% per year. This means that on average, a patient who has undergone ICL implantation can expect to lose approximately 1.8% of their endothelial cells each year following the procedure.³² It's important to note that this rate of loss should be viewed in the context of the expected age-related loss of ECD, which is 0.6% per year.³³ This means that even though the rate of loss is higher than what is typically seen with aging alone, it is still within the range of what is considered normal. Furthermore, the fact that no cases of corneal decompensation in the absence of trauma have been reported following ICL implantation is a positive sign for the long-term health of the corneal endothelium after this procedure. It suggests that even with the higher rate of cell loss, the remaining cells are able to compensate sufficiently to maintain corneal health and prevent decompensation.
 9. **Cataracts:** ICL surgery may increase the risk of developing cataracts later in life, however with the development of the EVO ICL, with the central port, has decreased the risk.³⁴ Safety data indicate that EVO lenses may reduce the occurrence of anterior subcapsular cataract (ASC) compared to earlier ICL models. A review of 38 peer-reviewed papers with safety data from retrospective and prospective studies on the EVO ICL, including 4196 eyes with up to 5 years of follow-up, showed that no patient developed a visually significant ASC, and only one eye experienced pupillary block due to retained viscoelastic.³⁵ It is important to recognize that high myopic patients often develop cataracts earlier in life. Cataract surgery can be very successful with the removal of the ICL and cataract, and with the insertion of a new intraocular lens.
 10. **Dislocation:** In rare cases, the ICL may shift out of position usually secondary to trauma.^{36,37} Surgical repositioning can restore the vision.

SUMMARY AND CLINICAL EXPERIENCE

A posterior chamber phakic implant is a highly effective option for patients seeking long-term refractive stability and safety, leading to improved uncorrected acuity. Although it is commonly used for high myopia, it can also be a viable option for patients with thin corneas, keratoconus, radial

keratotomy, pre-presbyopic hyperopes, and as a piggyback lens following cataract surgery and RLE. The refractive accuracy is comparable to that of fitting a contact lens on the cornea, and complications are minimal, resulting in a high benefit-to-risk ratio for patients. Patients also experience a high level of satisfaction due to the quick improvement in uncorrected acuity.

Additionally, by preserving the natural corneal curvature, the quality of vision is excellent both during the day

and at night. It is essential for clinicians to be knowledgeable about this innovative procedure so as to offer the best options to their refractive surgery patients and improve their quality of life.

Submitted: April 03, 2023 EDT, Accepted: May 09, 2023 EDT



This is an open-access article distributed under the terms of the Creative Commons Attribution 4.0 International License (CCBY-NC-4.0). View this license's legal deed at <https://creativecommons.org/licenses/by-nc/4.0> and legal code at <https://creativecommons.org/licenses/by-nc/4.0/legalcode> for more information.

REFERENCES

1. Packer M. The Implantable Collamer Lens with a central port: review of the literature. *Clinical Ophthalmology*. 2018;12:2427-2438. doi:10.2147/opt.h.s188785
2. Martínez-Plaza E, López-de la Rosa A, López-Miguel A, Holgueras A, Maldonado MJ. EVO/EVO+ Visian Implantable Collamer Lenses for the correction of myopia and myopia with astigmatism. *Expert Review of Medical Devices*. 2023;20(2):75-83. doi:10.1080/17434440.2023.2174429
3. Moshirfar M, Bundogji N, Tukan AN, et al. Toric implantable collamer lens for the treatment of myopic astigmatism. *Clinical Ophthalmology*. 2021;Volume 15:2893-2906. doi:10.2147/oph.s321095
4. Personal Communication, Dr Scott Barnes, Medical Director. *Staar Surgical*. Published online February 2023.
5. Fernández-Vega-Cueto L, Alfonso-Bartolozzi B, Lisa C, Madrid-Costa D, Alfonso JF. Seven-year follow-up of posterior chamber phakic intraocular lens with central port design. *Eye and Vis*. 2021;8(1):1-9. doi:10.1186/s40662-021-00247-1
6. Kamiya K, Shimizu K, Saito A, Igarashi A, Kobashi H. Comparison of optical quality and intraocular scattering after posterior chamber phakic intraocular lens with and without a central hole (Hole ICL and Conventional ICL) implantation using the double-pass instrument. *PLoS One*. 2013;8(6):e66846. doi:10.1371/journal.pone.0066846
7. Parkhurst GD, Psolka M, Kezirian GM. Phakic intraocular lens implantation in United States military warfighters: a retrospective analysis of early clinical outcomes of the Visian ICL. *J Refract Surg*. 2011;27(7):473-481. doi:10.3928/1081597x-20110106-03
8. Kamiya K, Shimizu K, Igarashi A, et al. Posterior chamber phakic intraocular lens implantation: comparative, multicentre study in 351 eyes with low-to-moderate or high myopia. *Br J Ophthalmol*. 2017;102(2):177-181. doi:10.1136/bjophthalmol-2017-310164
9. Brown DC, Ziémba SL, Collamer IOL FDA Study Group. Collamer intraocular lens: clinical results from the U.S. FDA core study. *J Cataract Refract Surg*. 2001;27(6):833-840. doi:10.1016/s0886-3350(01)00785-4
10. Chen X, Wang X, Xu Y, et al. Five-year outcomes of EVO implantable collamer lens implantation for the correction of high myopia and super high myopia. *Eye and Vis*. 2021;8(1):1-8. doi:10.1186/s40662-021-00264-0
11. Shi J. Meta-analysis of clinical efficacy after FS-LASIK and ICL implantation. *International Eye Science*. 2021:480-486.
12. Kamiya K, Shimizu K, Takahashi M, Ando W, Hayakawa H, Shoji N. Eight-year outcomes of implantation of posterior chamber phakic intraocular lens with a central port for moderate to high ametropia. *Front Med*. 2021;8. doi:10.3389/fmed.2021.799078
13. Alshamrani AA, Alharbi SS. Phakic intraocular lens implantation for the correction of hyperopia. *Journal of Cataract and Refractive Surgery*. 2019;45(10):1503-1511. doi:10.1016/j.jcrs.2019.05.051
14. Al-Shehri A, Aljohani S, Al-Mahmood A. Outcomes of implantable collamer lenses (ICL), femtosecond-assisted laser in situ keratomileusis (LASIK) and photorefractive keratectomy (PRK) for correction of hyperopia. *Journal of EuCornea*. 2020;9:17-22. doi:10.1016/j.xjec.2020.11.001
15. Fairaq R, Almutlak M, Almazayad E, Badawi AH, Ahad MA. Outcomes and complications of implantable collamer lens for mild to advance keratoconus. *Int Ophthalmol*. 2021;41(7):2609-2618. doi:10.1007/s10792-021-01820-2
16. Fadlallah A, Dirani A, El Rami H, Cherfane G, Jarade E. Safety and visual outcome of Visian toric ICL implantation after corneal collagen cross-linking in keratoconus. *J Refract Surg*. 2013;29(2):84-89. doi:10.3928/1081597x-20130117-01
17. Dirani A, Fadlallah A, Khoueir Z, Antoun J, Cherfan G, Jarade E. Visian toric ICL implantation after intracorneal ring segments implantation and corneal collagen crosslinking in keratoconus. *European Journal of Ophthalmology*. 2014;24(3):338-344. doi:10.5301/ejo.5000384
18. Rocha KM, Brown CE, Sioufi K, Gouvea L. Toric implantable collamer lens for treating refractive error in post-radial keratotomy, post-penetrating keratoplasty pseudophakic eye. *American Journal of Ophthalmology Case Reports*. 2020;20:100882. doi:10.1016/j.ajoc.2020.100882

19. Duncker GI, Sasse AC, Duncker T. A prospective pilot study using a low power piggy-back toric implantable Collamer lens to correct residual refractive error after multifocal IOL implantation. *Clinical Ophthalmology*. 2019;13:1689-1702. doi:10.2147/oph.s219738
20. Zhang H, Gong R, Zhang X, Deng Y. Analysis of perioperative problems related to intraocular Implantable Collamer Lens (ICL) implantation. *Int Ophthalmol*. 2022;42(11):3625-3641. doi:10.1007/s10792-022-02355-w
21. Vargas V, Alió del Barrio J, Alió JL. Complications of Phakic Intraocular Lenses. In: *Cataract Surgery: Advanced Techniques for Complex and Complicated Cases*. Springer International Publishing; 2022:165-175. doi:10.1007/978-3-030-94530-5_16
22. Navarrete Argüello J, Bello López Portillo H, Cantero Vergara MA, et al. Intraocular pressure fluctuations in patients implanted with an implantable collamer lens (ICL V4c). Three-month follow-up. *Archivos de la Sociedad Española de Oftalmología (English Edition)*. 2019;94(8):367-376. doi:10.1016/j.oftale.2019.05.004
23. Chen X, Wang X, Xu Y, et al. Long-term comparison of vault and complications of implantable collamer lens with and without a central hole for high myopia correction: 5 years. *Current Eye Research*. 2021;47(4):540-546. doi:10.1080/02713683.2021.2012202
24. Allan BD, Argeles-Sabate I, Mamalis N. Endophthalmitis rates after implantation of the intraocular Collamer lens: survey of users between 1998 and 2006. *Journal of Cataract and Refractive Surgery*. 2009;35(4):766-769. doi:10.1016/j.jcrs.2008.12.027
25. Zhang H, Gong R, Zhang X, Deng Y. Analysis of perioperative problems related to intraocular Implantable Collamer Lens (ICL) implantation. *Int Ophthalmol*. 2022;42(11):3625-3641. doi:10.1007/s10792-022-02355-w
26. Arrevola-Velasco L, Beltrán J, Rumbo A, et al. Ten-year prevalence of rhegmatogenous retinal detachment in myopic eyes after posterior chamber phakic implantable collamer lens. *J Cataract Refract Surg*. 2023;49(3):272-277. doi:10.1097/j.jcrs.000000000000001099
27. Srinivasan S. Pseudophakic retinal detachment: a ticking time bomb. *J Cataract Refract Surg*. 2023;49(3):225-226. doi:10.1097/j.jcrs.000000000000001157
28. Mohr N, Dirisamer M, Siedlecki J, et al. Determinants of Subjective Quality of Vision After Phakic Intraocular Lens Implantation. *J Refract Surg*. 2022;38(5):280-287. doi:10.3928/1081597x-20220405-01
29. Niu L, Zhang Z, Miao H, et al. Effects of tilt and decentration of Visian Implantable Collamer Lens (ICL V4c) on visual quality: an observational study. *BMC Ophthalmol*. 2022;22(1). doi:10.1186/s12886-022-02499-4
30. Goukon H, Kamiya K, Shimizu K, Igarashi A. Comparison of corneal endothelial cell density and morphology after posterior chamber phakic intraocular lens implantation with and without a central hole. *Br J Ophthalmol*. 2017;101(11):1461-1465. doi:10.1136/bjophthalmol-2016-309363
31. Yang W, Zhao J, Sun L, et al. Four-year observation of the changes in corneal endothelium cell density and correlated factors after Implantable Collamer Lens V4c implantation. *Br J Ophthalmol*. 2020;105(5):625-630. doi:10.1136/bjophthalmol-2020-031644
32. Moya T, Javaloy J, Montés-Micó R, Beltrán J, Muñoz G, Montalbán R. Implantable collamer lens for myopia: assessment 12 years after implantation. *J Refract Surg*. 2015;31(8):548-556. doi:10.3928/1081597x-20150727-05
33. Bourne WM, Nelson LR, Hodge DO. Central corneal endothelial cell changes over a ten-year period. *Invest Ophthalmol Vis Sci*. 1997;38(3):779-782.
34. Martínez-Plaza E, López-Miguel A, López-de la Rosa A, McAlinden C, Fernández I, Maldonado MJ. Effect of the EVO+ Visian phakic implantable Collamer lens on visual performance and quality of vision and life. *Am J Ophthalmol*. 2021;226:117-125. doi:10.1016/j.ajo.2021.02.005
35. Mandal S, Sahay P, Tripathi M, Maharana PK. Complications following implantation of posterior chamber phakic intraocular lens (pIOL). *BMJ Case Rep*. 2022;15(12):e253876. doi:10.1136/bcr-2022-253876
36. Alsugayhi M, Husain OB, Al-Swailem SA. Dislocation of implantable collamer lens following blunt trauma. *American Journal of Ophthalmology Case Reports*. 2023;29:101768. doi:10.1016/j.ajoc.2022.101768
37. Kojima T, Kitazawa Y, Nakamura T, et al. Multicenter survey on implantable collamer lens dislocation. *PLoS ONE*. 2022;17(2):e0264015. doi:10.1371/journal.pone.0264015